STUDY

Combination 532-nm and 1064-nm Lasers for Noninvasive Skin Rejuvenation and Toning

Min-Wei Christine Lee, MD, MPH

Background: Noninvasive techniques for skin rejuvenation are quickly becoming standard in the treatment of mild rhytids and overall skin toning. Multiple laser wavelengths and modalities have been used with varying degrees of success, including 532-nm, 585-nm, 1064-nm, 1320-nm, 1450-nm, and 1540-nm wavelengths.

Objectives: To evaluate a combination technique using a long-pulsed, 532-nm potassium titanyl phosphate (KTP) laser and a long-pulsed 1064-nm Nd:YAG laser, separately and combined, for noninvasive photorejuvenation and skin toning and collagen enhancement and to establish efficacy and degree of success.

Design: Prospective nonrandomized study with longitudinal follow-up.

Setting: Private dermatologic surgery and laser practice.

Methods: A total of 150 patients, with skin types I through V, were treated with long-pulsed KTP 532-nm and long-pulsed Nd:YAG 1064-nm lasers, separately and combined. For the KTP 532-nm laser, the fluences varied between 7 to 15 J/cm^2 at 7- to 20-millisecond pulse durations with a 2-mm handpiece and 6 to 15 J/cm^2 at 30- to 50-millisecond pulses with a 4-mm handpiece. The 1064-nm Nd:YAG laser fluences were set at 24 to 30 J/cm^2 for a 10-mm handpiece. These energies were delivered at 30- to 65-millisecond pulse durations. All subjects were treated at least 3 times and at most 6 times, depending on patient satisfaction level, at monthly intervals and were observed for up to 18 months after the last treatment.

Main Outcome Measures: All patients were asked to fill out a "severity scale" on which redness, pigmentation, rhytids, skin tone/tightness, texture, and patient satisfaction were noted before and after each treatment. Redness, pigmentation, rhytids, skin tone/tightness, and texture were also evaluated by the physician and another observer.

Results: After 3 to 6 treatments, 50 patients treated with the 532-nm KTP laser alone showed improvement of 70% to 80% in redness and pigmentation, 30% to 50% in skin tone/tightening, 30% to 40% in skin texture, and 20% to 30% in rhytids. Another 50 patients treated with the 1064-nm Nd:YAG laser alone showed improvement of 10% to 20% in redness, 0% to 10% in pigmentation, 10% to 30% in skin tone/tightening, 20% to 30% in skin texture, and 10% to 30% in rhytids. The third group of 50 patients treated with both KTP and Nd:YAG lasers showed improvement of 70% to 80% in redness and pigmentation, 40% to 60% in skin tone/tightening, 40% to 60% in skin texture, and 30% to 40% in rhytids. Skin biopsy specimens taken at 1-, 2-, 3-, and 6-month intervals demonstrated new collagen formation.

Conclusions: All 150 patients exhibited mild to moderate improvement in the appearance of rhytids, moderate improvement in skin toning and texture, and great improvement in the reduction of redness and pigmentation. The KTP laser used alone produced results superior to those of the Nd:YAG laser. Results from combination treatment with both KTP and Nd:YAG lasers were slightly superior to those achieved with either laser alone.

Arch Dermatol. 2003;139:1265-1276

From The East Bay Laser & Skin Care Center, Walnut Creek, Calif. The author has no relevant financial interest in this article.

THE MECHANISM of noninvasive or nonablative laser procedures involves the laser passing through the epidermis without any significant or damaging impact and inflicting thermal damage to the lower layers of dermis, thus encouraging the generation of collagen and resulting in tighter skin. The wavelengths used have ranged from 585 nm to 1540 nm, as well as flashlamp-delivered multiwavelength, intense pulsed light.[1-12] The wavelengths used for nonablative resurfacing target discrete chromophores such as melanin, hemoglobin, and water, and are capable of achieving a depth of penetration much deeper than that of either carbon dioxide or erbium:YAG (Er:YAG) lasers.

Anderson and Parrish[13] postulated that selective photothermolysis could be

Downloaded from www.archdermatol.com at SUNY Health Science Center, on July 12, 2007
©2003 American Medical Association. All rights reserved.

predicted by choosing the apropriate wavelength, pulse duration, and pulse energy for a particular target. For vascular lesions, the chromophore (target) is oxyhemoglobin. The peak absorptions of light energy for oxyhemoglobin are approximately 418, 542, and 577 nm.[14] Melanin absorbs light of shorter wavelengths more efficiently within the range of 250 to 1200 nm. The 532-nm wavelength selectively targets hemoglobin and melanin. The chromophores for 1064-nm radiation are, in decreasing order, melanin, hemoglobin, and water. However, the absorption coefficient of these chromophores for the 1064-nm wavelength is relatively lower than for other wavelengths. Less absorption by melanin and hemoglobin is balanced by greater depth of penetration, which in fact makes the near-infrared region ideal for selective dermal heating.

The advantage of combining 2 different laser modalities is that many of the elements of photodamage and photoaging can be addressed instead of only wrinkle reduction, which is only 1 visible component of photodamaged skin. Photodamage is the result of long-term UV light exposure creating damage to the epidermis and dermis with corresponding histologic and clinical changes. Using a nonablative resurfacing device to selectively treat facial rhytids addresses only 1 aspect of the photodamaged face. The overall effect is far more satisfying when all visible signs of photodamage and photoaging are treated (ie, telangiectasias, lentigines, solar elastosis, and wrinkling). In addition, combining the 2 different lasers creates a greater synergistic effect on collagen stimulation, than can be achieved by either laser alone, which results in superior toning, textural improvement, and wrinkle reduction.

The present study is the first to evaluate a technique using a long-pulsed 532-nm potassium titanyl phosphate (KTP) laser and a long-pulsed 1064-nm Nd:YAG laser, separately and combined, for noninvasive photorejuvenation and skin toning/collagen enhancement, and to establish efficacy and degree of success in a large cohort of patients with long-term follow-up.

METHODS

PRELIMINARY STUDIES

Preliminary studies were performed in the following manner: (1) 2 patients received 3 treatments with the KTP 532-nm laser at monthly intervals to one side of the face, while the contralateral side served as the control; (2) 2 patients received 3 treatments with the Nd:YAG 1064-nm laser to one side of the face, while the contralateral side served as the control; (3) 2 patients received 3 treatments with the KTP and Nd:YAG laser combination to one side of the face, while the contralateral side served as the control; (4) 2 patients received 3 treatments with the KTP laser on one side of the face and Nd:YAG on the other; (5) 2 patients received 3 treatments with KTP and Nd:YAG lasers combined on one side of the face and only KTP on the other; and (6) 2 patients received 3 treatments with KTP and Nd:YAG lasers combined on one side and only Nd:YAG on the other. Based on results seen in the preliminary studies, a large prospective study with long-term follow-up was undertaken. The results from the preliminary studies were similar to the results found in the large prospective study.

Another group of 6 patients received 3 to 6 treatments with the combined KTP and Nd:YAG lasers applied to the periorbital area only on one side of the face and the same lasers applied to the entire contralateral half of the face. The side receiving treatment to the entire half of the face demonstrated improved periorbital wrinkle reduction and tightening compared with the side that received only periorbital treatment.

PRIMARY STUDY

A total of 150 patients, aged 25 to 85 years (mean age, 48 years) with Fitzpatrick skin types I through V were entered into the study. Subjects were excluded if they had used oral retinoids within the past year, had a history of photosensitivity, or anticipated using other methods of skin rejuvenation during the treatment or follow-up period. Patients were also excluded if they were pregnant, predisposed to hypertrophic scars or keloids, or had a history of facial cosmetic procedures affecting the treatment areas within the last 2 years (ie, botulinum toxin, collagen, dermabrasion, chemical peeling, facial laser resurfacing, or face-lift). Patients with active skin disease within the treatment areas (ie, psoriasis, cancer, or autoimmune disease) were also excluded from the study.

All patients received complete information on the treatment and signed informed consent forms. No topical pretreatment was used in any patient. The posttreatment skin care regimen consisted of a gentle cleanser, moisturizer, and sunblock. Patients were instructed to apply mometasone ointment (Elocon; Schering Corp, Kenilworth, NJ) to any red, indurated, or swollen areas for 2 days only if needed; cold compresses were used to ease warmth and swelling.

Patients with a history of cold sores or fever blisters received a 10-day course of valacyclovir (Valtrex; GlaxoSmithKline, Research Triangle Park, NC), 500 mg twice daily, beginning 24 hours prior to the procedure as prophylaxis for herpes simplex infection. Hydroquinone and tretinoin were applied by patients with pigmentary disorders.

Prior to treatment, patients removed all makeup. A topical triple anesthetic gel composed of 20% benzocaine, 6% lidocaine, and 4% tetracaine (hereinafter, "BLT gel"; American Health Solutions Pharmacy, Los Angeles, Calif) was used in this study. Patients were offered topical anesthesia, which most accepted. As they became more comfortable with subsequent treatments, more patients elected not to have the topical treatment and still found the procedure quite tolerable. Care was taken to avoid contact of the BLT gel with the eye. Immediately prior to treatment, the BLT gel was removed.

During the procedure, chilled, colorless coupling gel was used to protect the epidermis and to aid in gliding the cooling tip over the surface of the skin. Patients were treated in the supine position with external eyeshields protecting their eyes. All patients had the entire face treated in each session.

Photographs were taken of every patient before and after each treatment. Fifteen patients were selected to undergo serial biopsies. Four-millimeter punch biopsies were performed in preauricular, postauricular, and inner arm locations. Specimens were taken at least 2 cm apart to ensure that biopsy wound healing would not affect adjacent biopsy sites. Sections were stained with hematoxylin-eosin. Verhoeff-van Gieson stain was used as well to highlight elastic fibers.

Long-pulsed KTP 532-nm (Aura; Laserscope, San Jose, Calif) and long-pulsed Nd:YAG 1064-nm (Lyra; Laserscope) lasers were used for these procedures. Both lasers use a sapphire window through which water at about 2°C to 6°C circulates allowing for continuous contact cooling. The reflective optics of the Lyra 10-mm handpiece walls bounce photons reflected from the skin back into the tissue (photon recycling). As a result of this photon recycling, the total

Downloaded from www.archdermatol.com at SUNY Health Science Center, on July 12, 2007
©2003 American Medical Association. All rights reserved.

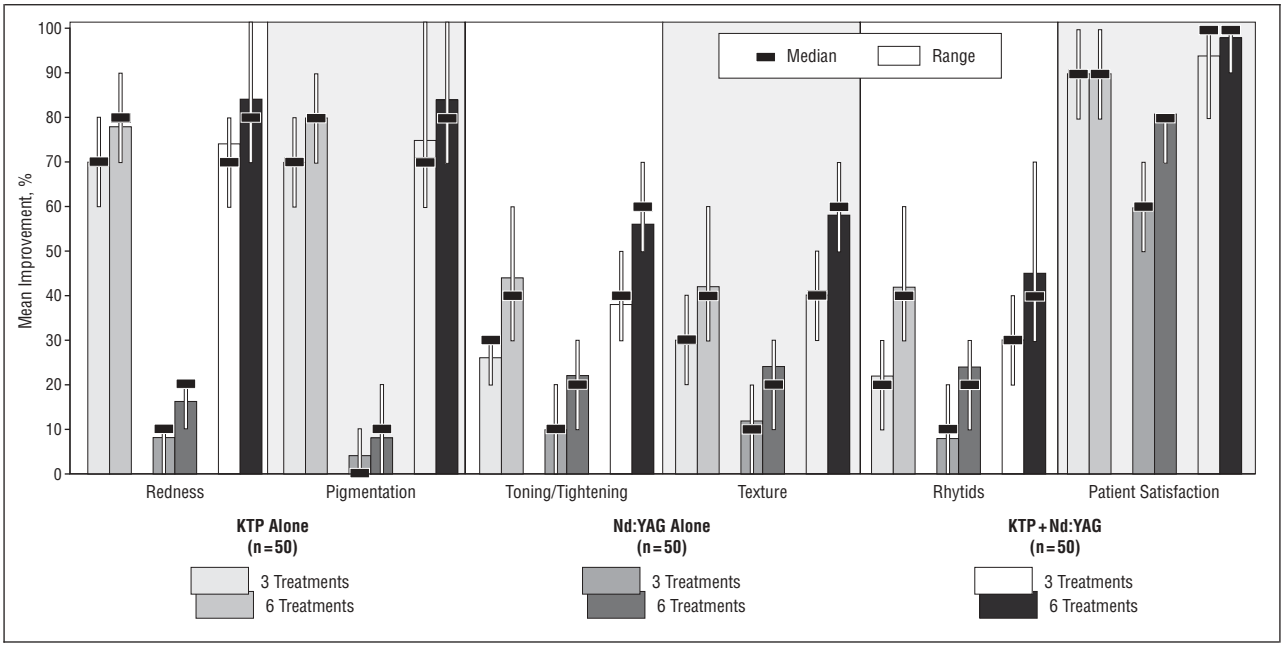

Figure 1. Percentage improvement in redness, pigmentation, tone/tightening, texture, rhytids, and patient satisfaction after multiple treatments with potassium titanyl phosphate (KTP) laser alone, Nd:YAG laser alone, and KTP and Nd:YAG combined (>6 months since the last treatment). The top of each bar represents the mean percentage improvement after 3 to 6 treatments.

Table 1. Percentage Improvement 6 Months After KTP Laser Treatment*

Clinical Parameter	Assessor	After 3 Treatments	After 6 Treatments	After 3-6 Treatments	No. of Patients
Redness	Investigator	68 (5)	72 (2.5)	70 (5)	50
	Subject	70 (5)	78 (5)	74 (7.5)	50
	Observer	62 (5)	70 (5)	66 (7.5)	50
Pigmentation	Investigator	66 (2.5)	76 (5)	71 (7.5)	50
	Subject	70 (5)	80 (5)	75 (7.5)	50
	Observer	70 (5)	78 (5)	74 (7.5)	50
Tone/tightening	Investigator	28 (5)	40 (5)	34 (7.5)	50
	Subject	24 (2.5)	46 (5)	35 (7.5)	50
	Observer	26 (2.5)	44 (7.5)	35 (10)	50
Texture	Investigator	30 (5)	42 (7.5)	36 (10)	50
	Subject	32 (5)	42.4 (5)	37.2 (7.5)	50
	Observer	25.6 (7.5)	43.6 (7.5)	34.6 (10)	50
Rhytids	Investigator	20.4 (7.5)	38 (5)	29.2 (12.5)	50
	Subject	22.8 (7.5)	37.6 (7.5)	30.2 (15)	50
	Observer	22 (5)	32 (7.5)	27 (12.5)	50

Abbreviation: KTP, potassium titanyl phosphate.
*Unless otherwise indicated, data are mean (SD) percentages; $P<.001$ for all categories.

energy applied to the tissue is estimated to be increased by about 1.5 times.

A total of 150 patients were treated in 3 groups: 50 patients were treated with the 532-nm laser alone; 50 were treated with the 1064-nm laser alone; and 50 were treated with both lasers together. Patients with Fitzpatrick skin types I through IV were enrolled in this evaluation for the first and third groups involving the 532-nm laser, and those with skin types I through V for the 1064-nm laser group. This skin type restriction was necessary because the KTP laser is well absorbed by melanin and can be problematic in treating darker skin types. The longer-wavelength Nd:YAG laser alone can safely be applied to skin types V and VI.

Three to 6 treatments were applied in each group, with 4- to 6-week intervals between treatments. The number of treatments was based on patient satisfaction level. All patients filled out a "severity scale," using a scale from 0 to 10 to evaluate redness, pigmentation, rhytids, skin tone/tightening, skin texture, and overall satisfaction before the first treatment, after each treatment, and at the 3-, 6-, and 12-month follow-up after the final treatment. A total of 94 patients (63%) were observed for up to 18 months. Redness, pigmentation, rhytids, skin tone/tightness, and texture were also evaluated using the same scale by the physician and another observer. Ratings were given after viewing comparison photographs.

The group of patients treated with the KTP laser alone was first evaluated for sun damage, telangiectatic vessels, and other skin inconsistencies. There were 25 patients with skin types I and II and 25 patients with skin types III and IV. The first pass was done with the 2-mm handpiece to remove individual lesions such as lentigines and telangiectasias. The desired end points were blanching of vascular lesions and a slight whitening over the pigmented lesions.

Downloaded from www.archdermatol.com at SUNY Health Science Center, on July 12, 2007
©2003 American Medical Association. All rights reserved.

Table 2. Percentage Improvement 6 Months After Nd:YAG Laser Treatment*

Clinical Parameter	Assessor	After 3 Treatments	After 6 Treatments	After 3-6 Treatments	No. of Patients
Redness	Investigator	6 (2.5)	10 (5)	8 (5)	50
	Subject	8 (2.5)	16 (2.5)	12 (5)	50
	Observer	4 (2.5)	12 (5)	8 (5)	50
Pigmentation	Investigator	2 (2.5)	4 (2.5)	3 (2.5)	50
	Subject	4 (2.5)	8 (5)	6 (5)	50
	Observer	3.2 (2.5)	5.6 (5)	4.4 (5)	50
Tone/tightening	Investigator	11.2 (5)	28 (5)	19.6 (7.5)	50
	Subject	8.4 (5)	20.8 (5)	14.6 (7.5)	50
	Observer	10 (5)	22 (5)	16 (7.5)	50
Texture	Investigator	8 (2.5)	14 (2.5)	11 (5)	50
	Subject	12 (5)	24 (2.5)	18 (7.5)	50
	Observer	6 (2.5)	12 (2.5)	9 (5)	50
Rhytides	Investigator	6 (2.5)	18.8 (5)	12.4 (7.5)	50
	Subject	8 (5)	24 (2.5)	16 (7.5)	50
	Observer	6.8 (5)	20.4 (5)	13.6 (7.5)	50

*Unless otherwise indicated, data are mean (SD) percentages; $P<.001$ for all categories.

Table 3. Percentage Improvement 6 Months After Combination KTP and Nd:YAG Laser Treatments*

Clinical Parameter	Assessor	After 3 Treatments	After 6 Treatments	After 3-6 Treatments	No. of Patients
Redness	Investigator	74 (7.5)	84 (7.5)	79 (10)	50
	Subject	82 (5)	90 (5)	86 (7.5)	50
	Observer	78 (5)	88 (5)	83 (7.5)	50
Pigmentation	Investigator	76 (7.5)	86 (7.5)	81 (10)	50
	Subject	78 (5)	88 (5)	83 (7.5)	50
	Observer	75.2 (10)	84 (7.5)	79.6 (10)	50
Tone/tightening	Investigator	36.4 (5)	48.8 (10)	42.6 (10)	50
	Subject	38 (5)	56 (7.5)	47 (10)	50
	Observer	37.6 (5)	48 (10)	44.8 (10)	50
Texture	Investigator	39.2 (5)	52 (7.5)	45.6 (10)	50
	Subject	40 (5)	58 (7.5)	49 (10)	50
	Observer	41.2 (5)	52.4 (7.5)	46.8 (10)	50
Rhytides	Investigator	32 (5)	48.4 (10)	40.2 (12.5)	50
	Subject	31.2 (5)	50 (10)	40.6 (12.5)	50
	Observer	30 (5)	45.2 (10)	37.6 (12.5)	50

Abbreviation: KTP, potassium titanyl phosphate.
*Unless otherwise indicated, data are mean (SD) percentages; $P<.001$ for all categories.

The laser parameters were set at 10 to 20 milliseconds and 10 to 15 J/cm^2 for telangiectasia and 7 to 10 milliseconds and 7 to 10 J/cm^2 for lentigines. Once individual blemishes and discolorations were individually treated, a 4-mm handpiece with contact cooling was used at 30 to 50 milliseconds and 6 to 15 J/cm^2 (depending on skin type) in a "brushstroke" or "sweeping" manner over the entire face, applying 2 to 4 passes over areas with more damage. This was done to even out the skin color of the entire face. Immediately after the treatment, ice packs were placed on the face for 15 to 20 minutes, followed by the application of mometasone ointment to the treated areas.

The second group of patients was treated with the Nd:YAG wavelength alone. This group included 25 patients with skin types I and II, 20 patients with skin types III and IV, and 5 patients with skin type V. A 10-mm spot size handpiece with a sapphire contact cooling window at 5°C delivered 30- to 65-millisecond pulses at 24 to 30 J/cm^2 (depending on skin type, severity of rhytids, and anatomic area). The handpiece was used over the entire face in a brushstroke manner. The entire face was treated at each session except in some of the male subjects who elected to avoid treatment of the beard region because of potential hair loss.

The third patient group was treated with the combination of the 2 lasers. This group included 25 patients with skin types I and II and 25 patients with skin types III and IV. Patients with skin types V or VI were excluded. All patients in this group were treated with KTP laser to the entire face exactly per the protocol of the first group, immediately followed by treatment with the Nd:YAG to the entire face as described in the protocol for the second group.

In all patients treated, certain precautions were taken around the eye area. External eye shields were placed. Care was taken to always stay outside of the orbital rim by treating above the eyebrow and outside the lateral canthus. For treatment of the lower eyelids, the skin was retracted downward from the lower lid, and the laser beam was always pointed away from the globe and below the infraorbital rim. In patients with severe periorbital rhytids, internal corneal eyeshields were inserted prior to treatment of the periorbital region with the KTP. This was never attempted with the Nd:YAG because it is such a deeply penetrating wavelength that even internal eye shields would not be protective.

With the 1064-nm wavelength, gauze was placed inside the patient's mouth to protect the teeth and fillings. Also, certain areas—such as thinning temporal and forehead regions—

Downloaded from www.archdermatol.com at SUNY Health Science Center, on July 12, 2007
©2003 American Medical Association. All rights reserved.

Figure 2. A 38-year-old woman before (A) and 6 months after (B) 3 treatments with combined potassium titanyl phosphate (KTP) and Nd:YAG lasers. Note the overall improvement in erythema, pigmentation, skin tone and texture, pore tightening, and fine wrinkles.

Figure 3. A 65-year-old woman before (A) and 6 months after (B) 6 treatments with combined potassium titanyl phosphate (KTP) and Nd:YAG lasers. Note the improvement in pigmentation, skin tone and texture, and periorbital tightening and rhytid reduction.

Downloaded from www.archdermatol.com at SUNY Health Science Center, on July 12, 2007
©2003 American Medical Association. All rights reserved.

Figure 4. A 51-year-old woman before (A) and 6 months after (B) 6 treatments with combined potassium titanyl phosphate (KTP) and Nd:YAG lasers. Note the overall improvement in erythema, pigmentation, skin tone and texture, pore tightening, and rhytid reduction.

were treated more conservatively or avoided. For statistical analysis, χ^2 and paired *t* tests were used to compare groups, with a critical *P* value of .05.

RESULTS

The first group of 50 patients was treated with the KTP laser alone. After 3 to 6 treatments, they showed improvement of 70% to 80% in redness and pigmentation, 30% to 50% in skin tone/tightening, 30% to 40% in skin texture, 20% to 30% in rhytids, and 80% to 100% patient satisfaction. The second group of 50 patients was treated with the Nd:YAG laser alone. They showed improvement of 10% to 20% in redness, 0% to 10% in pigmentation, 10% to 30% in skin tone/tightening, 20% to 30% in skin texture, 10% to 30% in rhytids, and 60% to 80% patient satisfaction. The third group, treated with both KTP and Nd:YAG lasers, showed improvement of 70% to 80% in redness and pigmentation, 40% to 60% in skin tone/tightening, 40% to 60% in skin texture, 30% to 40% in rhytids, and 80% to 100% patient satisfaction (**Figure 1**). Statistically significant improvement in all categories was observed in all 3 groups ($P<.001$ for all) (**Tables 1**, **2**, and **3**). Also, there were statistically significant differences among the 3 groups: KTP and Nd:YAG in combination yielded greater results than either used alone, and KTP alone was superior to Nd:YAG alone.

Figures 2, **3**, and **4** show the typical improvement in redness, telangiectasias, pigmentation, toning/tightening, texture, fine wrinkles, and pore size after a series of full-face treatments with the combined KTP and Nd:YAG lasers. **Figure 5** and **Figure 6** demonstrate the benefits of using dual lasers compared with a single laser in split-face comparisons.

Skin biopsy specimens taken at 1-, 2-, 3-, and 6-month intervals demonstrated new collagen and elastin formation. Four patients had serial biopsies performed along both inner upper arms in the following sequence: before treatment (control site), immediately after treatment, 1 week, 1 month, 2 months, 3 months, 6 months, and 12 months after 1 treatment, 3 treatments, and 6 treatments with KTP alone, Nd:YAG alone, and KTP and Nd:YAG combined. The tissue samples pictured from this series (**Figure 7**) are from the inner arms of a 51-year-old woman and are representative of all samples. New collagen was observed not only in the papillary dermis but throughout the full thickness of the reticular dermis. The papillary dermis and dermal collagen were much thicker, more densely packed, more organized and horizontally arranged, and also contained new elastic fibers. The amount of collagen and elastin more than doubled after 6 treatments with KTP and Nd:YAG combined. There was also an enlargement of underlying blood vessels that support the skin.

When compared with a control site without treatment, a specimen from a site that underwent 6 treatments with KTP and Nd:YAG lasers combined had tighter, more densely packed fibers bundled in a more parallel array (Figure 7). Measurements were taken of the zone of new collagen formed in the papillary dermis and of the entire dermis extending from the basement membrane to the beginning of subcutaneous fat in specimens that underwent 6 treatments with KTP alone and 6 Nd:YAG treatments alone and 6 KTP and Nd:YAG combined treatments. It is apparent that the amount of collagen formed is far greater after combination therapy and with a greater number of passes (**Figure 8** and **Figure 9**). The papillary dermal zone of new collagen averaged 100 to 200 µm. **Table 4** summarizes the measurements of the band of new collagen formed beneath the epidermis after series of treatments in the various groups. Elastin stains revealed increased amounts of elastic fibers deposited throughout the papillary and reticular dermis after multiple treatments (**Figure 10**). Finer strands indicative of reticulin (or collagen type 3) which is associated with more elastic and supple new collagen formation consistent with normal youthful skin were seen on higher magnification (**Figure 11**).

Tables 5, **6**, and **7** summarize the adverse effects encountered. No hypopigmentation or scarring was noted in this study. Mild erythema and edema were present by 5 minutes after treatment in most subjects. Patient reports indicated that the erythema and edema faded completely within several hours to 3 days after treatment. These effects were generally mild enough that subjects experienced no limitations in their activities. Patients with rosacea had more significant erythema and swelling after treatment that also lasted longer in proportion to the severity of rosacea. Only 4 of the 150 patients had mod-

Downloaded from www.archdermatol.com at SUNY Health Science Center, on July 12, 2007
©2003 American Medical Association. All rights reserved.

Figure 5. Before (A) and 6 months after (B) 6 treatments with combined potassium titanyl phosphate (KTP) and Nd:YAG lasers to right side of face and Nd:YAG alone to left. Note the greater improvement in pigmentation, skin tone and texture, and rhytid reduction on the right side of the face, especially the right periorbital region.

erate to severe erythema and swelling that resulted in down time of 2 to 3 days. These 4 patients had severe rosacea with a strong vasoactive component. They reported being more sensitive to heat and trigger factors. With subsequent treatments, the amount of erythema and edema experienced by these 4 patients diminished, probably owing to a decreased vascular component resulting in less absorption of KTP energy.

Besides minor erythema, KTP laser treatment also resulted in temporary discoloration from darkening of lentigines and ephelides, which formed a slight whitening immediately after treatment and then sloughed off after 7 days. Patients with Fitzpatrick skin types III and IV occasionally had postinflammatory hyperpigmentation that resolved after 4 to 6 weeks. This was directly related to sun exposure. Although patients were advised to use sunscreens and to avoid sun exposure during the entire study, some patients were noncompliant. Eleven patients with skin types III and IV had sun exposure after treatments, which caused immediate recurrence of freckles. With improved sun avoidance, these freckles cleared after repeated treatments and remained clear. Four patients with melasma had initial improvement followed by recurrence of pigmentation related to hormonal supplements. Once the hormonal therapy was discontinued, the laser treatments were successful. Hyperpigmentation cleared faster when adjunctive posttreatment therapy included hydroquinone and tretinoin.

Pain was rated as mild to moderate by all subjects (mean score, 5.3 of 10). After applying ice packs and mometasone ointment, patients had no residual sensations. Without ice packs and mometasone, patients reported mild burning or stinging for several minutes to several hours after treatment. No subject reported the use of any pain medication to relieve discomfort.

Eight patients (20%) with severe rosacea started to demonstrate recurrence of flushing and telangiectasias 6 months to a year after their last treatment. Twenty-six patients (20%) with preexisting photodamage started to show early signs of recurrence (telangiectasias, freckling, and rhytids) 6 months to a year after their last treatment, depending on lifestyle factors and adherence to sun avoidance instructions. Most patients in all groups maintained the improvements made after their last treatment up to the 1-year follow-up. Sixty patients (40%) with improved tone/tightening, texture, and rhytid reduction reported better results at 6 months than at 3 months after the last treatment. Thirty patients (20%) demonstrated regression of improvements made in tone/tightening, texture, and rhytid reduction after 9 months; but even after 18 months, none had regressed to baseline (appearance prior to treatment). In summary, all patients showed improvement over baseline at

Downloaded from www.archdermatol.com at SUNY Health Science Center, on July 12, 2007
©2003 American Medical Association. All rights reserved.

Figure 6. Before (A) and 6 months after (B) 6 treatments with combined potassium titanyl phosphate (KTP) and Nd:YAG lasers to the right side of the face, and KTP alone to the left side. Note the overall improvement in erythema and slightly greater periorbital tightening and rhytid reduction of the upper lip on the right side.

the 1-year posttreatment follow-up, but not all patients were able to maintain the highest level of improvement that had been achieved.

COMMENT

A number of studies have indicated that although it appears that nonablative laser resurfacing achieves histologically demonstrable dermal collagen remodeling, this collagen remodeling does not always seem to correlate with significant clinical improvement.[11,15-17] Trelles et al[17] reported disappointing results after treating 10 patients with a 1320-nm Nd:YAG laser in a series of 8 treatments over a 4-week period, with only 2 of 10 patients expressing satisfaction with the results of their treatment. However, Trelles[18] followed up with a letter to the editor indicating that unpublished long-term data showed better results than the preliminary study, and that 4 weeks was not sufficient time to draw conclusions about the efficacy of the treatments.

Goldberg[15] reported a clinical and histologic study of 10 patients treated with a 1320-nm Nd:YAG laser, with all 10 patients reporting subjective improvement but 4 patients showing no apparent improvement by objective determination at 6-month follow-up. Goldberg noted that clinical improvement was not always directly correlated with the observed histologic changes in his study or in other studies he had participated in.[7,8,15,16]

Menaker et al[11] treated 10 patients with a novel 1320-nm Nd:YAG laser in a series of 3 treatments at 2-week intervals. Three months after treatment, 4 of 10 patients showed improvement, but the results were not statistically significant, and 3 patients developed pitted scarring as a complication from the laser treatments.

The inconsistent results reported in prior studies on Nd:YAG lasers are similar to the findings from the group treated with Nd:YAG alone in the present study. Patients treated with Nd:YAG alone had a lower level of satisfaction than patients treated with KTP and Nd:YAG lasers combined. Similar to the findings by Fatemi et al[19] that treating sites with increased temperatures and multiple passes produced better clinical results, the present study showed that combining the strength of 2 lasers and increasing the number of passes and the fluences produced better clinical outcomes.

Patient satisfaction was very high with the full-face treatments described in the present study. This satisfaction corresponded to improvement detected by the clinician and an outside observer using objective criteria. Historically, many patients have reported decreased satisfaction with partial face treatments performed with the lasers used in the present study in addition to other commonly used nonablative devices (unpublished data, 2001).

Downloaded from www.archdermatol.com at SUNY Health Science Center, on July 12, 2007
©2003 American Medical Association. All rights reserved.

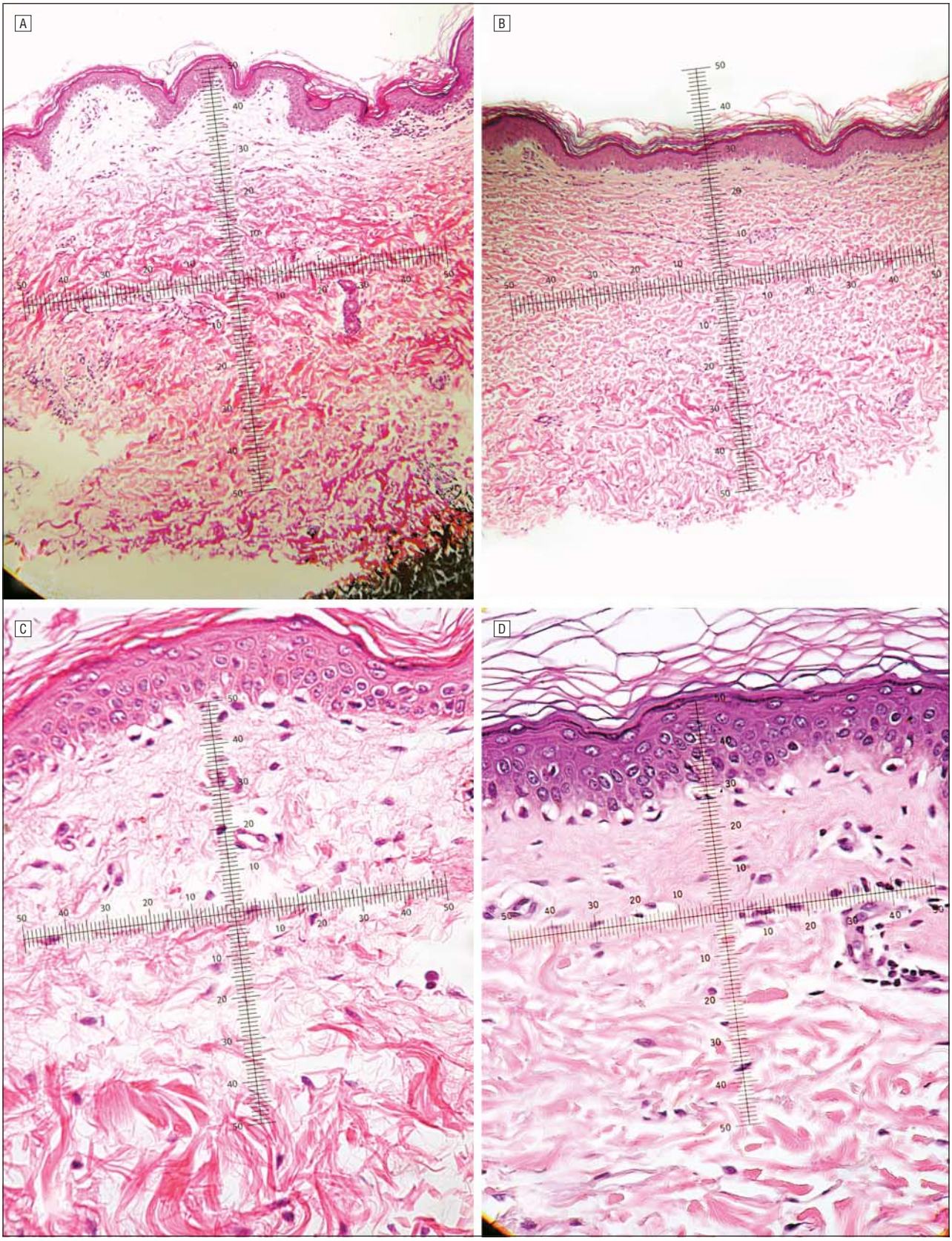

Figure 7. Biopsy specimens of inner arm skin of a 51-year-old woman before (A) and 6 months after (B) 6 treatments with combined potassium titanyl phosphate (KTP) and Nd:YAG lasers. Note the thicker, more densely packed papillary and dermal collagen as well as new elastic fibers (hematoxylin-eosin, original magnification ×10, each scale mark indicates 20 μm). At greater magnification before (C) and 6 months after (D) 6 treatments with combined KTP and Nd:YAG lasers, note the new band of denser and horizontally oriented collagen just below the epidermis, measuring about 150 to 200 μm (hematoxylin-eosin, original magnification ×40, each scale mark indicates 5 μm).

Downloaded from www.archdermatol.com at SUNY Health Science Center, on July 12, 2007
©2003 American Medical Association. All rights reserved.

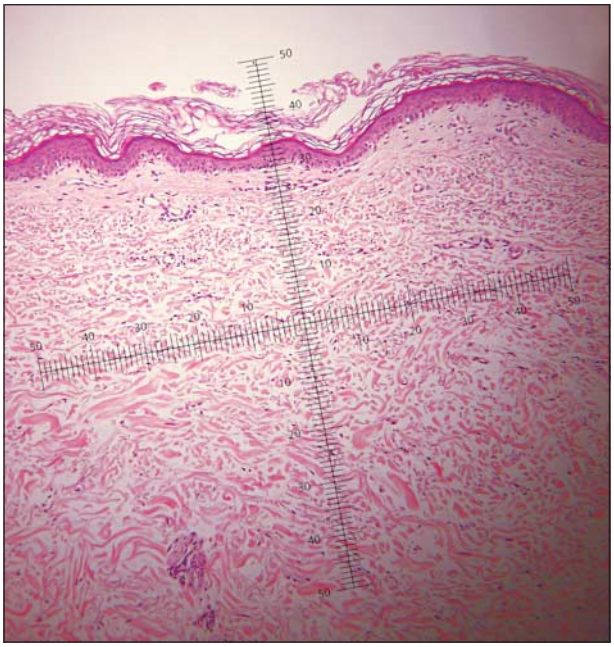

Figure 8. Biopsy specimen from the inner arm skin 6 months after 6 treatments with potassium titanyl phosphate laser alone. The band of new subepidermal collagen measures about 100 µm (hematoxylin-eosin, original magnification ×10, each scale mark indicates 20 µm).

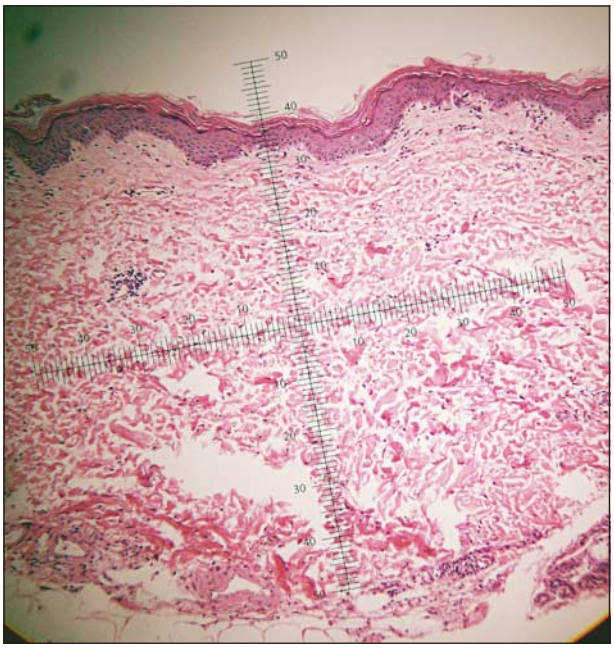

Figure 9. Biopsy specimen from the inner arm skin 6 months after 6 treatments with Nd:YAG laser alone. The new band of papillary dermal collagen is thinner (50-80 µm) than that in the site treated with the potassium titanyl phosphate laser alone (see Figure 8), and the dermal collagen is less densely packed (hematoxylin-eosin, original magnification ×10, each scale mark indicates 20 µm).

This is supported by findings reported by Bitter,[4] who performed serial, full-face, intense pulsed light treatments with high patient satisfaction. The advantage of full-face treatment is that it creates overall collagen remodeling and thus improves wrinkle reduction in localized regions (ie, periorbital) compared with results when only isolated areas are treated. Treatment of only the periorbital region with a series of 3 to 6 treatments of the combined KTP and Nd:YAG lasers achieved less satisfactory wrinkle reduction than treatment of similar rhytids using the same lasers to treat the entire face.

Table 4. Measurements of New Collagen Formation

Mean (SD) Papillary Collagen Zone, µm	No. of Treatments	Laser(s) Used
60 (20)	3	KTP
100 (50)	6	KTP
50 (25)	3	Nd:YAG
80 (40)	6	Nd:YAG
100 (50)	3	KTP and Nd:YAG
200 (50)	6	KTP and Nd:YAG

Abbreviation: KTP, potassium titanyl phosphate.

An important distinction needs to be made between the terms *noninvasive rejuvenation* or *photorejuvenation* and *nonablative resurfacing* and *wrinkle reduction*. Noninvasive rejuvenation includes nonablative resurfacing and wrinkle reduction, but the converse is not true. Most devices used to perform nonablative resurfacing do not cause any epidermal surface change; instead, they focus mainly on collagen remodeling. Nonablative wrinkle reduction does not necessarily include photorejuvenation. The 1064-nm Nd:YAG laser treatment used in this study stimulates collagen production and results in wrinkle reduction but does not address the visible signs of photodamage. The KTP laser treatment used in this study addresses both collagen production and photorejuvenation. However, the 2 lasers combined seem to have a synergistic effect on collagen production, yielding more satisfactory results.

The energy from both lasers is absorbed in microvasculature within the dermal papillae and dermis, with KTP mainly targeting more superficial and smaller vessels and Nd:YAG absorbed in deeper layers. This absorption in blood increases the temperature around the vessels, transferring thermal damage to the surrounding tissue and causing the release of inflammatory chemical mediators that stimulate the collagen healing process. There is also direct stimulation of fibroblasts by laser energy to produce more collagen. Bjerring et al[5] suggested that inflammatory mediators released from vascular endothelial cells damaged by the laser might cause new dermal collagen production by fibroblasts. There is also some nonspecific thermal damage from the scattering effect from both lasers that was seen in several biopsy specimens taken during the present evaluation.

Patient satisfaction was much higher with the KTP laser owing to the more visual effects of epidermal change in addition to the benefits from collagen remodeling. However, the application of the longer wavelength energy brought benefits as well. The Nd:YAG laser, by penetrating to the deeper dermis, stimulated underlying vasculature and epidermal and dermal cell–specific injury resulting in further augmentation of skin tightening, smoother texture, and improved appearance of mild rhytids.

Collagen remodeling can continue for 6 to 12 months after traumatic stimulation of fibroblasts. The clinical and

Downloaded from www.archdermatol.com at SUNY Health Science Center, on July 12, 2007
©2003 American Medical Association. All rights reserved.

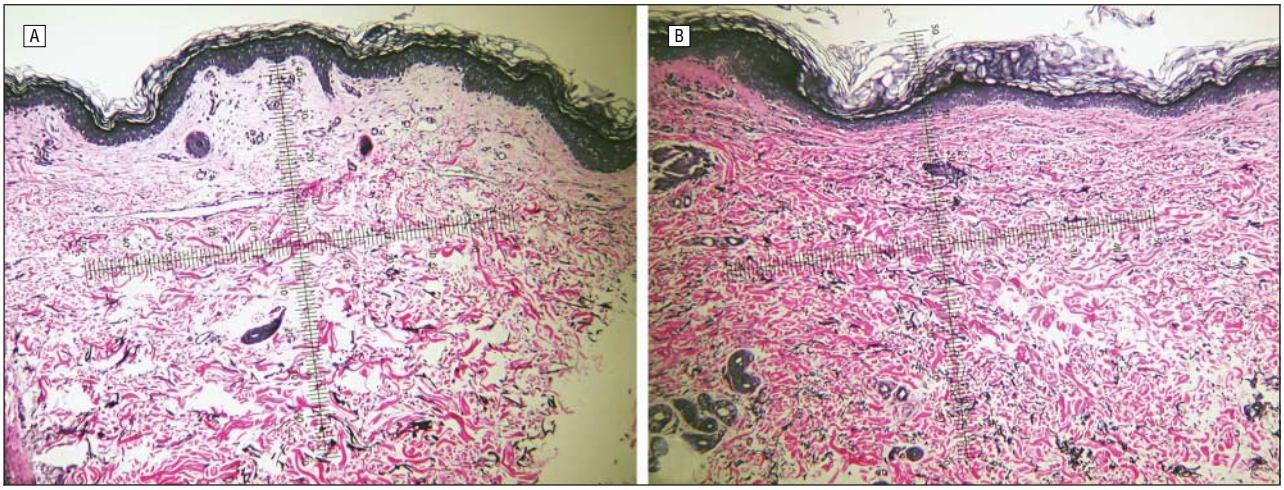

Figure 10. Verhoeff-van Gieson stain highlighting elastin fibers in biopsy specimens of inner arm skin before (A) and 6 months after (B) 6 treatments with combined potassium titanyl phosphate and Nd:YAG lasers. The fibers are thicker, tighter, and bundled in a more parallel array (original magnification ×10, each scale mark indicates 20 μm).

Figure 11. Finer strands of reticulin interspersed among elastic and collagen fibers (Verhoeff-van Gieson, original magnification ×100).

histologic results from the present study show that collagen remodeling is a gradual process that increases proportionately with the number of treatments, intensity of treatments, and elapsed time. A falling out occurs at around 9 months, when this process reaches a threshold and starts to regress. There is a loss of improvements made clinically in skin tone/tightening, texture, and rhytid reduction that corresponds to a plateau followed by regression seen in collagen thickening histologically. The regression occurs gradually but does not return to baseline at 18 months' follow-up. If one ex-

Table 5. Adverse Effects Following Laser Treatment With KTP Alone

Adverse Effect	No. (%) Reported (n = 50)
Temporary swelling	
None	18 (36)
Mild	20 (40)
Moderate	10 (20)
Severe	2 (4)
Temporary erythema	
None	5 (10)
Mild	35 (70)
Moderate	9 (18)
Severe	1 (2)
Temporary hyperpigmentation*	6 (12)
Hypopigmentation	0
Blisters	1 (2)
Scarring	0

Abbreviation: KTP, potassium titanyl phosphate.
*Does not include darkening of pigmented lesions that form an eschar and slough off after 7 days.

Table 6. Adverse Effects Following Laser Treatment With Nd:YAG Alone

Adverse Effect	No. (%) Reported (n = 50)
Temporary swelling	
None	30 (60)
Mild	20 (40)
Moderate	0
Severe	0
Temporary erythema	
None	16 (32)
Mild	34 (68)
Moderate	0
Severe	0
Temporary hyperpigmentation	0
Hypopigmentation	0
Blisters	0
Scarring	0

Downloaded from www.archdermatol.com at SUNY Health Science Center, on July 12, 2007
©2003 American Medical Association. All rights reserved.

Table 7. Adverse Effects Following Laser Treatment With KTP and Nd:YAG Combined

Adverse Effect	No. (%) Reported (n = 50)
Temporary swelling	
None	12 (24)
Mild	25 (50)
Moderate	11 (22)
Severe	2 (4)
Temporary erythema	
None	4 (8)
Mild	34 (68)
Moderate	11 (22)
Severe	1 (2)
Temporary hyperpigmentation*	5 (10)
Hypopigmentation	0
Blisters	2 (4)
Scarring	0

Abbreviation: KTP, potassium titanyl phosphate.
*Does not include darkening of pigmented lesions that form an eschar and slough off after 7 days.

trapolated these data to longer time periods, it might become apparent that biologic and photoaging inevitably continue, but performing a series of combined laser treatments can alter some of the damage created by long-term UV exposure and stimulate collagen production, which essentially turns back the clock. However, this improvement is not permanent because of the continual passage of time and forces associated with aging and UV exposure. Patients with rosacea or frequent sun exposure will have much faster recurrence of problems and need more frequent maintenance treatments.

Further long-term studies are needed to assess the ability to maintain collagenesis and remodeling with continual laser treatments. Further studies are already under way (1) to investigate longer-term effects of additional serial treatments of noninvasive lasers used in combination; (2) to determine the maximum duration of results that can be maintained; (3) to discover if there is a maximum number of treatments that the skin can tolerate; (4) to augment the effects of the combined laser procedure with skin care products and other technologies; and (5) to assess the results of multiple series of treatments followed by maintenance treatments in the future.

Accepted for publication May 14, 2003.

This study was presented at the American Society for Dermatologic Surgery Annual Meeting; October 26, 2001; Dallas, Tex; and the American Society for Laser Medicine and Surgery Annual Meeting; April 13, 2002; Atlanta, Ga.

I thank Philip E. LeBoit, MD, for his help reading and interpreting the histopathologic results of this study.

Corresponding author and reprints: Min-Wei Christine Lee, MD, MPH, The East Bay Laser & Skin Care Center, 1479 Ygnacio Valley Rd, Suite 209, Walnut Creek, CA 94598 (e-mail: eastbaylaser@aol.com).

REFERENCES

1. Goldberg DJ. Non-ablative subsurface remodeling: clinical and histologic evaluation of a 1320nm Nd:YAG laser. *J Cutan Laser Ther.* 1999;1:153-157.
2. Zelickson BD, Kilmer SL, Bernstein E, et al. Pulsed dye laser therapy for sun damaged skin. *Lasers Surg Med.* 1999;25:229-236.
3. Sumian CC, Pitre FB, Gauthier BE, Bouclier M, Mordon SR. Laser skin resurfacing using a frequency doubled nd:yag laser after topical application of an exogenous chromophore. *Lasers Surg Med.* 1999;25:43-50.
4. Bitter PH. Noninvasive rejuvenation of photodamaged skin using serial, full-face itnense pulsed light treatments. *Dermatol Surg.* 2000;26:835-843.
5. Bjerring P, Clement M, Heickendorff L, et al. Selective non-ablative wrinkle reduction by laser. *J Cutan Laser Ther.* 2000;2:9-15.
6. Goldberg DJ. New collagen formation after dermal remodeling with an intense pulsed light source. *J Cutan Laser Ther.* 2000;2:59-61.
7. Goldberg DJ, Whitworth J. Laser skin resurfacing with the Q-switched Nd:YAG laser. *Dermatol Surg.* 1997;23:903-907.
8. Goldberg DJ, Silapunt S. Histologic evaluation of a Q-switched Nd:YAG laser in the nonablative treatment of wrinkles. *Dermatol Surg.* 2001;27:744-746.
9. Fournier N, Dahan S, Barneon G, et al. Nonablative remodeling: clinical, histologic, ultrasound imaging, and profilometric evaluation of a 1540 nm Er:glass laser. *Dermatol Surg.* 2001;27:799-806.
10. Ross EV, Sajben FP, Hsia J. Non-ablative skin remodeling: selective dermal heating with a mid-infrared laser and contact cooling combination. *Lasers Surg Med.* 2000;26:186-195.
11. Menaker G, Wrone DA, Williams RM, Moy R. Treatment of facial rhytids with a nonablative laser: a clinical and histologic study. *Dermatol Surg.* 1999;25:440-444.
12. Kelly KM, Nelson JS, Lask GP, et al. Cryogen spray cooling in combination with nonablative laser treatment of facial rhytids. *Arch Dermatol.* 1999;135:691-694.
13. Anderson RR, Parrish JA. Selective photothermolysis: precise microsurgery by selective absorption of pulsed radiation. *Science.* 1983;220:524-527.
14. Anderson RR, Parrish JA. Microvasculature can be selectively damaged using dye lasers: a basic theory and experimental evidence in human skin. *Lasers Surg Med.* 1981;1:263-276.
15. Goldberg DJ. Full-face nonablative dermal remodeling with a 1320nm Nd:YAG laser. *Dermatol Surg.* 2000;26:915-918.
16. Goldberg DJ. Non-ablative subsurface remodeling: clinical and histologic evaluation of a 1320-nm Nd:YAG laser. *J Cutan Laser Ther.* 1999;1:153-157.
17. Trelles MA, Allones I, Luna R. Facial rejuvenation with a nonablative 1320 nm Nd:YAG laser: a preliminary clinical and histologic evaluation. *Dermatol Surg.* 2001;27:111-116.
18. Trelles MA. Short and long-term follow-up of nonablative 1320 nm Nd:YAG laser facial rejuvenation [letter]. *Dermatol Surg.* 2001;27:781-782.
19. Fatemi A, Weiss MA, Weiss, RA. Short-term histologic effects of nonablative resurfacing: results with a dynamically cooled millisecond-domain 1320 nm Nd:YAG laser. *Dermatol Surg.* 2002;28:172-176.

Downloaded from www.archdermatol.com at SUNY Health Science Center, on July 12, 2007
©2003 American Medical Association. All rights reserved.

involved a nonimmunocompromised host, may be attributable to the patient's use of a coarse brush and partly to his poorly controlled atopic dermatitis.[4,5]

Yasuki Tateishi, MD
Department of Dermatology
Hokkaido University
Graduate School of Medicine
N15 W7, Kita-ku, Sapporo 060-8638, Japan
(e-mail: y-tateishi@k7.dion.ne.jp)

Hidetsugu Sato, MD
Obihiro, Japan

Masashi Akiyama, MD, PhD
Sapporo

Masataka Abe, MD
Hajime Kobayashi, MD
Shintaro Umehara, MD
Jun Yamaguchi, MD, PhD
Obihiro

Hideomi Shibaki, MD, PhD
Hiroshi Shimizu, MD, PhD
Sapporo

The authors have no relevant financial interest in this article. Reprints are available from Dr Tateishi.

1. Grossman ME, Pappert AS, Garzon MC, Silvers DN. Invasive *Trichophyton rubrum* infection in the immunocompromised host: report of three cases. *J Am Acad Dermatol.* 1995;33:315-318.
2. Akiba H, Motoki Y, Satoh M, Iwatsuki K, Kaneko F. Recalcitrant trichophytic granuloma associated with NK-cell deficiency in a SLE patient treated with corticosteroid. *Eur J Dermatol.* 2001;11:58-62.
3. Hay RJ. Chronic dermatophyte infections, I: clinical and mycological features. *Br J Dermatol.* 1982;106:1-7.
4. Erbagci Z. Deep dermatophytoses in association with atopy and diabetes mellitus: Majocchi's granuloma tricophyticum or dermatophytic pseudomycetoma? *Mycopathologia.* 2002;154:163-169.
5. Grigoriu D, Delacrétaz J, Borelli D. Deep generalized dermatophytosis. In: *Medical Mycology*. Toronto, Canada: Hans Huber Publishers; 1987:143-152.

Correction

Duplicate Publication of Figures and Tables. The article by Lee titled "Combination 532-nm and 1064-nm Lasers for Noninvasive Skin Rejuvenation and Toning," published in the October ARCHIVES (2003;139:1265-1276), had figures, tables, and portions of the text previously published in *Seminars in Cutaneous Medicine and Surgery* (Lee MW. Combination visible and infrared lasers for skin rejuvenation. 2002;21:288-300), which should have been noted. Figures 1, 4, 7, 10, and 11 and Tables 4 through 7 are reprinted with permission from Elsevier.

Downloaded from www.archdermatol.com at SUNY Health Science Center, on July 12, 2007
©2004 American Medical Association. All rights reserved.